



Viti i IX-të | Botimit, Nr.1,
Qershore 2018

FACIAL CONTOUR RECOVERY BY LIPOFILLING: A CLOSED LOOP SYSTEM PROTOCOL

Claudio Taglia*, Claudio Matteini*, Claudio Rinna*, Maurizio Perugini*, Paolo Di Curzio*, ERDA QORRI ** Mario Goisis*

*Belcolle Hospital Viterbo Department of Maxillo Facial Surgery

**Albanian University, Department of dentistry

Corresponding author: info@claudiomatteini.it

Abstract

Since Coleman¹ first introduced the use of free flat graft to improve aesthetic contour in the face this technique is widely adopted.

The authors reports their experience with a closed loop system technique.

The main advantages of such technique are represented by no post treatment infections rate, less invasivity due to smaller needle used both for the graft and the fill and moreover no centrifugation of the grafting is required.

Goisis' technique results less invasive with no hematomas, minor algic symptoms, overall a better patients' compliance.

Keywords: *graft, aesthetic, closed loop system technique.*

KONTURI FACIAL I REGJENERUAR ME LIPOFFILING: PROTOKOLLI I NJË SISTEMI TË MBYLLUR

Përmbledhje

Coleman¹ ishte i pari që futi përdorimin e graftit të sheshtë të lirë për të rritur estetikën e konturit facial, që atëherë kjo teknikë gjeti një përhapje të shpejtë.

Autorë të ndryshëm ndajnë përvojën e tyre me teknikën sipas sistemit të mbyllur.

Avantazhi kryesor i një teknike të tillë është mungesa e infeksionit pas trajtimit, invazivitet i ulët falë ageve më të vogla të përdorura si për graftin dhe fillerin dhe mbi të gjitha nuk nevojitet centrifugimi i graftit. Teknikae Gosis është edhe më pak invazive me mungesën e hematomës, simptoma dhimbje me të vogla, por mbi të gjitha pajtueshmëri më të mirë me pacientin.

Fjalë çelës: *graft, estetikë, teknikë e mbyllur.*

Introduction

Since Coleman¹ first introduced the use of free flat graft to improve aesthetic contour in the face this technique is widely adopted in practical clinic for merely aesthetic purposes or as an help in reconstructive surgery.^{2,3,4}

This technique is appreciated both by specialists and patients due to the fact it is a minimally invasive procedure and can be easily performed under local anaesthesia and provides immediate results at a low cost, with a rapid clinical recovery and an improved patient's compliance.

The main problem with this procedure is represented by its unpredictability due to the variable degree of resorption ranging from 45% to 80% ^{5,6}.

The wide world application of such procedure has increased the variability of the procedures, one of these proposed by M. Goisis since 2016 and provides the use of a closed loop system.

Material and methods


In our practice we have adopted the Goisis' protocol in the treatment of 12 female patients affected by aging with zygomatic volume loss, with an age from 36 to 72 years (average 47,5), between January and March 2017.

The harvesting of fat graft is provided by 10cc syringe with multi perforated blunt tip cannula with a diameter of 2 mm rounded. The 6 holes have a diameter 0,6 mm with a spiral disposition that allows the aspiration with rotatory movements and not only piston movements.

The microfat is injected with a 22 gauge 7 cm long blunt cannula.

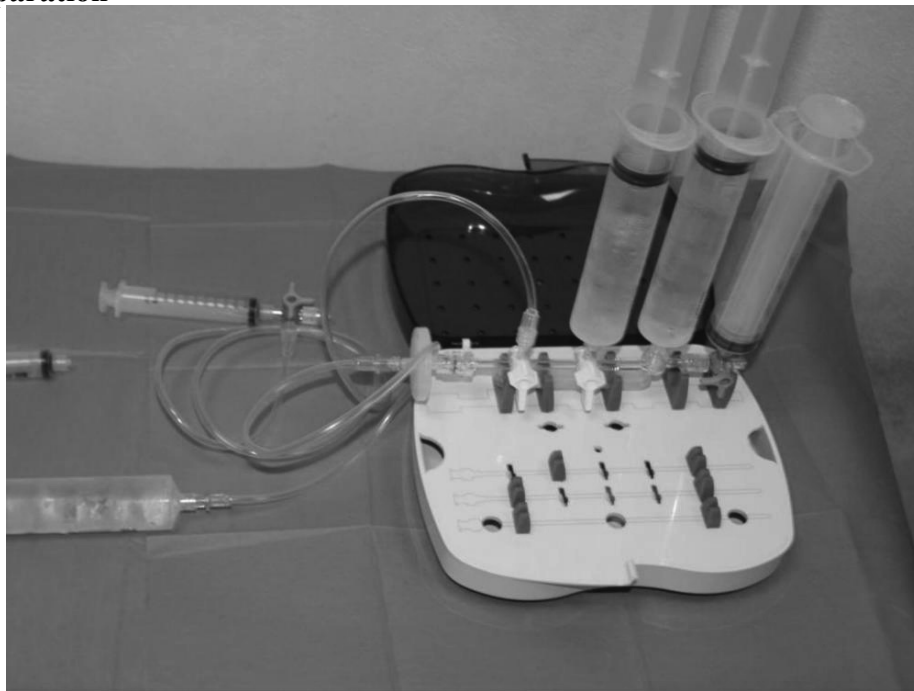
The Goisis' protocol has 9 steps to be performed:

Step 1: Arranging the contents



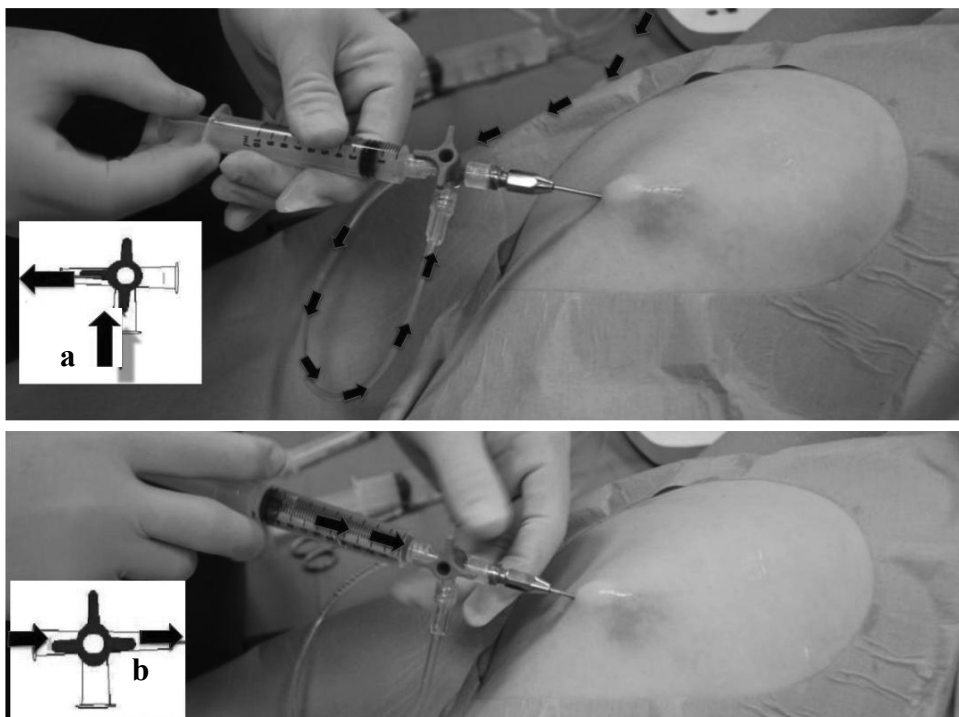
- Open and dispose the content of the box onto the sterile field: the manifold is connected to:
A, B and C: direct connection with 60 cc syringes
D: filter and tube connected with a 60 cc syringe
E: tube connected with a stopcock and a 10 cc syringe

Step 2: Preparation



syringes A and D are filled by local anaesthesia syringe B is filled by saline solution

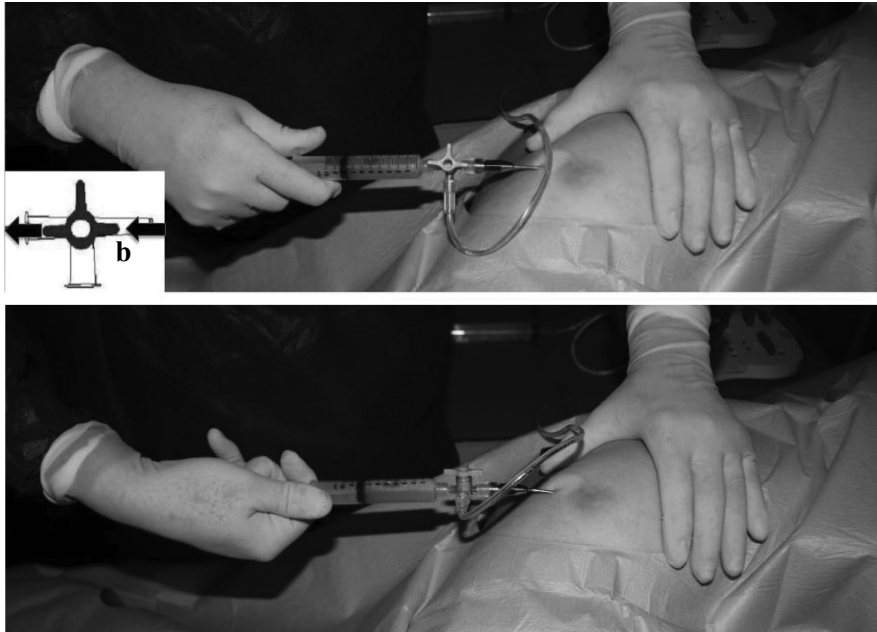
Step 3: Anaesthesia



The local anaesthetic is transferred directly from Syringes A and D to the syringe E. Because the system is completely closed, the risks of infection are reduced.

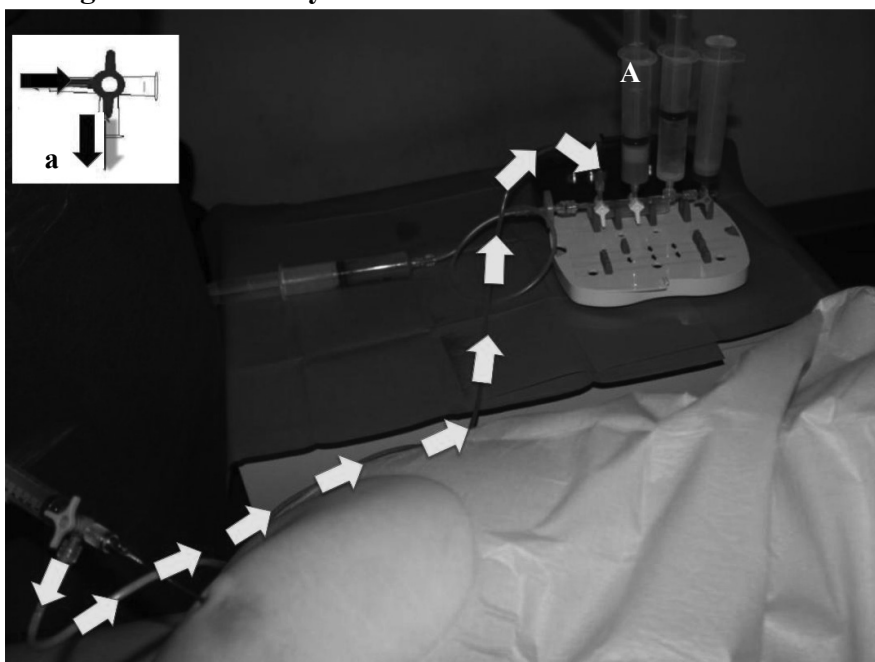
In particular, when the stopcock is in position “a”, by pulling the plunger, the syringe is filled by anaesthetic solution. By moving the stopcock in position “b” the anaesthetic solution is rapidly injected. In this way, all the infiltration of anaesthesia takes 5 minutes of operating time.

Step 4: Fat harvesting



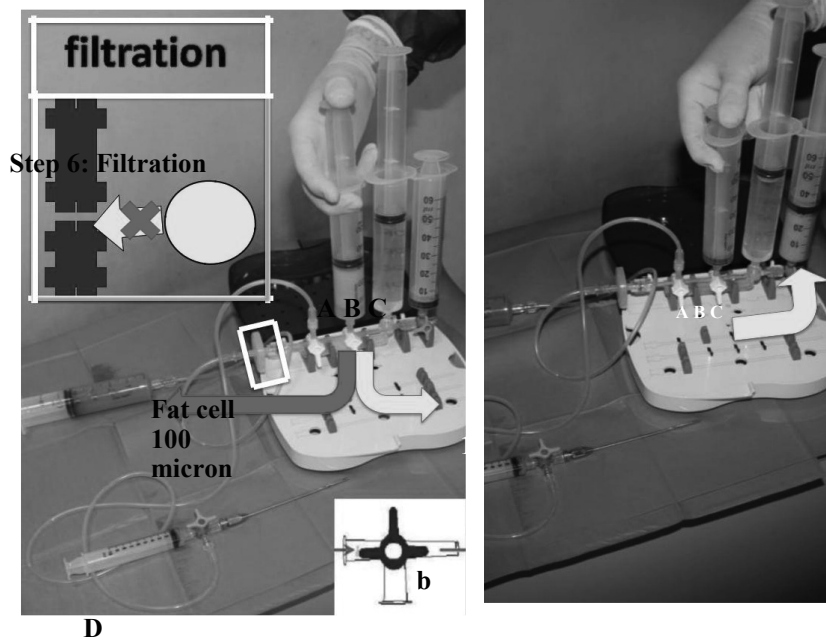
For fat harvesting, the plunger of syringe E is retracted. The negative pressure is maintained and the syringe is progressively filled by fat. The stopcock is in position “b”.

Step 5: Transferring of fat into the system



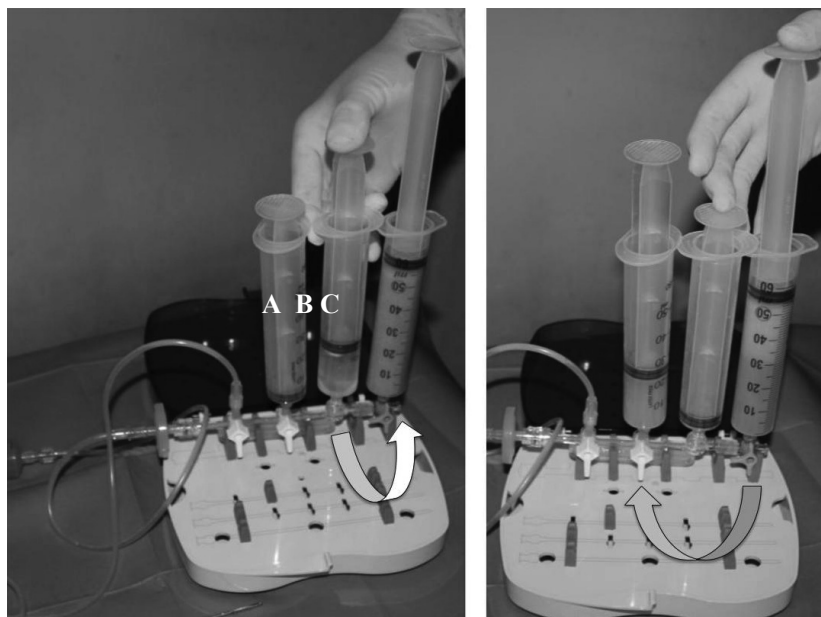
When the syringe is completely filled, move the stopcock in position “a”. The fat mixed with blood and anaesthesia is pushed and transferred directly from the syringe E to the syringe A.

Step 6: Filtration



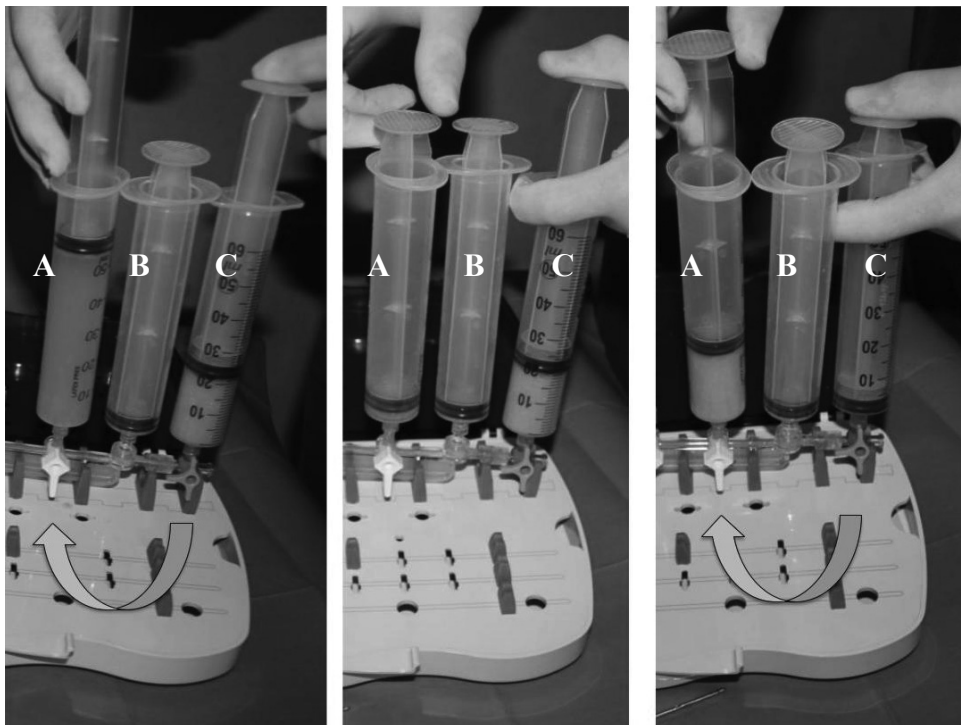
The stopcock of Syringe E is moved in position “b”. Then, push down on the plunger of syringe A. Because of the filter, most of the blood cells and anaesthesia are automatically directed to the syringe D (red arrow). At the opposite, the fat cells are moved to the syringe C (yellow arrow). All is automatic and there is no need to move stopcocks or valves.

Step 7: Washing



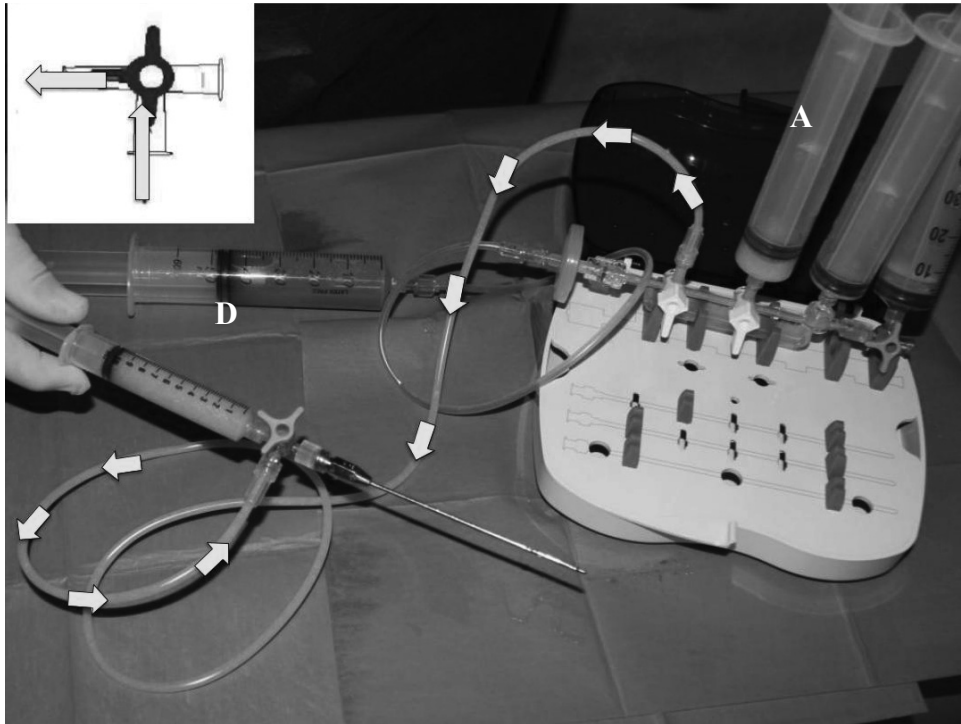
Push the plunger of syringe B. This will automatically draw saline solution into the syringe C. Wait 60 seconds, then push down on the plunger to move out the content of the lower part of the syringe C. In fact, because of separation by gravity, in the lower part of syringe are concentrated blood, water and local anaesthesia. A check valve automatically directs these elements to syringe A and to filter. Wait for 60 seconds the separation between fat and water, and repeat the procedure. The colour of fat which is in syringe C move from orange to yellow.

Step 8: Second filtration



Remove the content of syringe A. Then push down on the plunger of syringe C. The residual water is squeezed out to the filter. At the opposite, the fat cells are moved to the syringe A. All is automatic and there is no need to move stopcocks or valves.

Step 9: Injecting the fat



Move the stopcock of the syringe 6 from position “b” to position “a”. Then, the fat is automatically transferred from syringe.

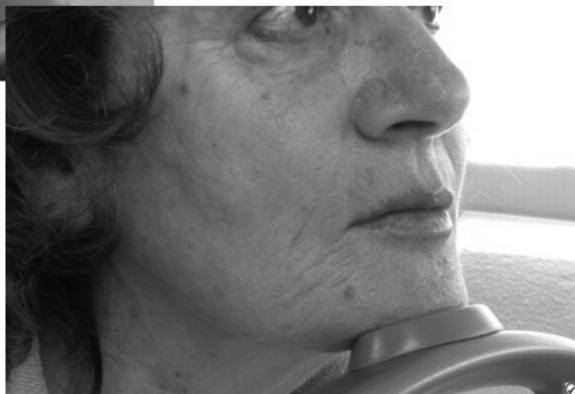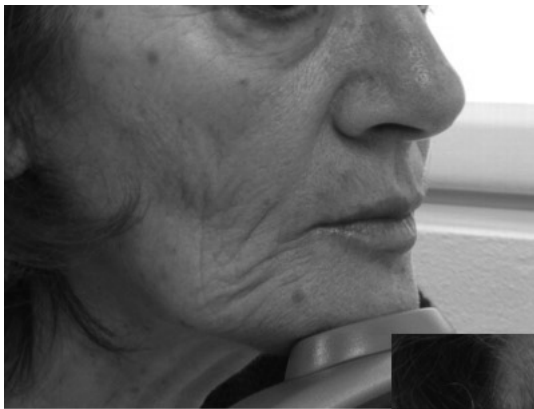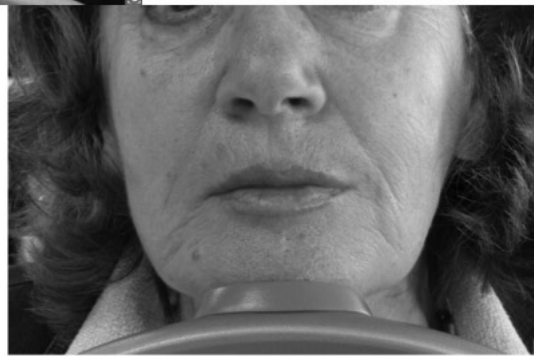Results

Any complication was detected in our sample of patients, the average recovery (edema) period was 7 days.

No hematomas were detected.

Minor pain symptoms at the pressure were registered in the donor site with an average last of 8 days.

The results achieved were absolutely satisfying.





Discussion and conclusion

Fat grafting is extensively used in plastic and reconstructive surgery, the use of fat filler is the golden standard for many authors⁶⁻⁷.

The success of fat grafting in the clinical practice is motivated by the desire of establishing an ideal approach, which may guarantee optimal and rapid outcomes with low complications rate according and high patient's compliance¹.

In our experience the use of the protocol previously described is a quick, easy and safe technique with good results.

In our experience this protocol represents a valid alternative to the more usually adopted protocols. Due to the fact that introduces a closed loop system, reduces the infections risk.

The main advantage of this protocol, however, is the smaller diameter of the needles used both for the lipo-aspiration and for the grafting.

The graft in the Coleman's technique is provided by needle with a diameter of 3 mm and the graft has larger particulate adipose cells that need to be centrifuged, in the Goisis' technique the graft aspiration is performed by cannula with a diameter of 2 mm, no centrifugation is of the grafting required.

For the filling in the Coleman's techniques is provided 1,2 mm in the Goisis' one cannula is with smaller diameter 22 gauge.

The Goisis' technique results less invasive with no hematomas, less algic symptoms, overall a better patients' compliance, and it safer for any contamination risk.

References

1. Coleman SR Facial recontouring with lipostructure. *Clin Plast Surg* 1997;24:347.
2. Gir P, Brown SA, Oni G, et al. Fat grafting: evidence-based review on autologous fat harvesting, processing, reinjection, and storage. *Plast Reconstr Surg*. 2012; 130:249–258.
3. Del Vecchio D, Rohrich RJ. A classification of clinical fat grafting: different problems, different solutions. *Plast Reconstr Surg*. 2012;130:511–522.
4. Strong AL, Cederna PS, Rubin JP, et al. The current state of fat grafting: a review of harvesting, processing, and injection techniques. *Plast Reconstr Surg*. 2015;136:897–912.
5. Krastev TK, Beugels J, Hommes J, Piatkowski A, Mathijssen I, van der Hulst R. Efficacy and Safety of Autologous Fat Transfer in Facial Reconstructive Surgery: A Systematic Review and Meta-Analysis. *Facial Plast Surg*. 2018 Mar 29. doi: 10.1001/jamafacial.2018.0102. [Epub ahead of print]
6. Ibrahiem SMS, Farouk F, Salem IL Facial rejuvenation: Serial fat graft transfer. *Alexandria Journal of medicine* (2016) 52:371-376.
7. Pereira LH, Nicaretta B, IllouzYC. Clinical application of autologous fat transplantat. In Illouz YZ, Sterodimas A, ed. *Adipose stem cells and regenerative medicine*. 7th ed. Berlin Heidelberg: Springer-Verlag 2011 p.57-65.